

PATIENT PRESENTING CLINICAL SIGNS

Molly Vandenberg

History: No abnormalities on abdominal palpation at last visit -Previous U/S by focal Zone July 20/22 identified a 3 cm non-disruptive hypoechoic liver nodule as well as a non-distended gallbladder with mild echogenic sludge Current Medications Zentonil (patient does not tolerate Ursodiol)
Abnormal PE/Chem/CBC/UA Results: Jan28/23 Alkp 991 (5-160) alkp had been at 611 at HREVC Aug/22, and 752 in July/22, 500 in April/22. ALT has always been WNL abnormal snap cpl identified at HREVC Aug/22

SPECIES

Canine

BREED

Terrier mix

SEX

Female, spayed

AGE

12 Yrs.

WEIGHT

7.8 kg.

ULTRASONOGRAPHIC EXAMINATION OF THE ABDOMEN

Urinary System

The urinary bladder and visible portion of the pelvic urethra are normal for the degree of luminal distension. The urine is anechoic with no evidence of debris. Cystic calculi and discrete masses are not observed. The region of the trigone and the visible portion of the proximal urethra are normal.

The left kidney is normal in size (4.02 cm in length) with a normal shape, smooth peripheral margins and normal internal architecture. There is mild to moderate loss of corticomedullary distinction. Several hyperechoic shadowing diverticular foci are observed. There is no evidence of pyelectasia, infarcts or hydronephrosis. Renal vasculature is normal.

The right kidney is normal size (4.57 cm in length) with a normal shape, smooth peripheral margins and normal internal architecture. There is mild to moderate loss of corticomedullary distinction. Several hyperechoic shadowing diverticular foci are observed. There is no evidence of pyelectasia, infarcts or hydronephrosis. Renal vasculature is normal.

Adrenal Glands

The left adrenal gland is borderline enlarged (0.59 cm at cranial pole) (0.61 cm at caudal pole) (2.20 cm in length); normal shape; homogenous parenchyma. The glandular echogenicity and detail are unremarkable. Capsule, cortex, and medullary definition are normal. The phrenicoabdominal vein and surrounding vasculature are normal.

The right adrenal gland is borderline enlarged (1.55 cm at cranial pole) (0.57 cm at caudal pole) (2.15 cm in length); normal shape; homogenous parenchyma. The glandular echogenicity and detail are unremarkable. Capsule, cortex, and medullary definition are normal. The phrenicoabdominal vein and surrounding vasculature are normal.

Spleen

The spleen is normal in size (1.56 cm in width at the level of the hilus) with a normal capsular contour. There is appropriate echogenicity and echotexture. No focal lesions are observed. Splenic vasculature is normal.

Liver

The liver is normal to slightly prominent in size with normal curvilinear peripheral contours. The parenchyma is isoechoic relative to the spleen and subtly heterogeneous in appearance. A 2.71 cm hypoechoic nodule/mass is observed on the left side. The lesion does not appear to cause capsular expansion. Vascular and biliary tracts are of normal volume with no evidence of congestion. The gall bladder lumen is moderately distended. The wall is thin and smooth. A small amount of gravity-dependent echogenic debris/sludge is observed within the lumen. The cystic and common bile ducts are normal/not seen.

Gastrointestinal

INTERPRETED BY

Andrea Nicastro, DVM,
Diplomate ACVIM
(Small Animal Internal
Medicine)

IMAGING PERFORMED BY

Kelly Reshcny

HOSPITAL NAME

Stoney Ridge AH

REFERRING VET

Dr. Brooks

DATE

2/14/23



PATIENT

Molly Vandenberg

The gastric lumen is not distended. The gastric wall is normal in thickness with a normal layering pattern. The small intestinal lumen is not dilated. The small intestinal wall thickness is normal with a normal layering pattern and appropriate mural detail. Discreet masses are not identified. The colonic wall is normal. There is no evidence of an obstructive pattern.

SPECIES

Canine

Pancreas

The region of the pancreas is isoechoic relative to surrounding omental fat. No obvious parenchymal abnormalities are observed. There is no evidence of regional inflammation or effusion.

BREED

Terrier mix

Free Abdomen

The peritoneal cavity is normal. There is no evidence of inflammation or effusion. The abdominal lymph nodes are normal/not visible.

SEX

Female, spayed

AGE

12 Yrs.

ULTRASONOGRAPHIC FINDINGS

Primary Findings:

- Left hepatic nodule/mass. Differentials include tumor (i.e., adenoma, adenocarcinoma), regenerative nodule, granuloma, inflammatory focus, other. The lesion is similar in size compared to the previous sonogram.
- Minor gallbladder sludge, non-mucocele.

WEIGHT

7.8 kg.

Secondary Findings:

- Bilateral chronic renal changes with dystrophic mineralization.

INTERPRETED BY

Andrea Nicastro, DVM,
Diplomate ACVIM
(*Small Animal Internal
Medicine*)

INTERPRETATION OF THE FINDINGS & FURTHER RECOMMENDATIONS

- Consider a fine needle aspirate of the left hepatic nodule/mass, if accessible and if clotting status is appropriate. A 25 gauge needle should be used.
- Also consider three-view thoracic radiographs to evaluate for pulmonary metastatic disease.
- If further diagnostics are not pursued at this time, liver values should be monitored (i.e., every 3 months). In addition, a recheck ultrasound is also recommended in 3 months to assess for growth of the hepatic lesion.
- Consider testing for hyperadrenocorticism with a low-dose dexamethasone suppression test or ACTH stimulation test if clinical signs (i.e., PU/PD) develop in the future.

IMAGING PERFORMED BY

Kelly Reshcny

HOSPITAL NAME

Stoney Ridge AH

REFERRING VET

Dr. Brooks

DATE

2/14/23



PATIENT

Molly Vandenberg

SPECIES

Canine

BREED

Terrier mix

SEX

Female, spayed

AGE

12 Yrs.

WEIGHT

7.8 kg.

INTERPRETED BY

Andrea Nicastro, DVM,
Diplomate ACVIM
(Small Animal Internal
Medicine)

**IMAGING
PERFORMED BY**

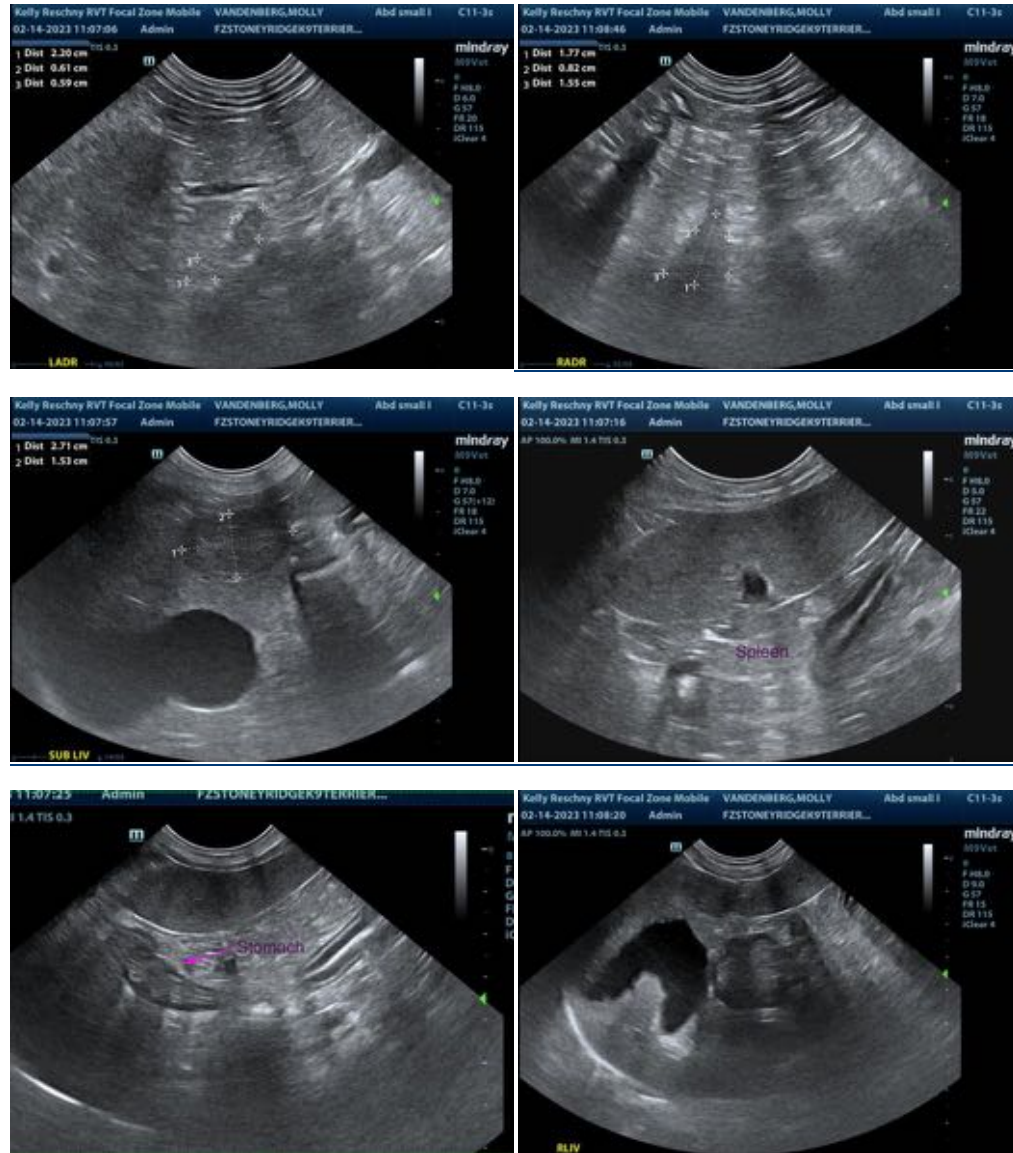
Kelly Reshcny

HOSPITAL NAME

Stoney Ridge AH

REFERRING VET

Dr. Brooks



The information and recommendations provided are based on the images presented by the referring veterinarian/sonographer. No evaluation can be communicated regarding pathology that was not visible in the image/video clips provided.

Thank you for this referral. If the clinical or image interpretation does not parallel your findings or if I can be of any further assistance please contact me.

Andrea Nicastro, MPH, DVM, Diplomate DACVIM (Small Animal Internal Medicine)
info@SonoPath.com

DATE

2/14/23